

Received: January 03, 2017
Accepted: January 19, 2017
Published: February 01, 2017

Fetal Echography Remotely Controlled Using A Tele-Operated Motorized Probe and Echograph Unit

Philippe Arbeille^{1,*}, Jose Ruiz², Gabriel Carles³, Victorita Stefanescu⁴, Monica Georgescu¹

¹UMPS-CERCOM, Faculte de Medecine, 37032, Tours, France

²Dept Ostetrica i Gynecologia, Hospital de Ceuta, Spain.

³Sce Obstetrique et Gynecologie, Hopital ouest guyanais St Laurent du Maroni, Guyane, France.

⁴Pediatric Hospital, Galate, Romania.

*Corresponding author: Philippe Arbeille, Professor, Faculty of the Medecine, Blv Tonnelle, 37032-Tours – France. Tel: +33 680 105 488, E-mail: arbeille@med.univ-tours.fr

1 Abstract

1.1 Objective

to evaluate the performance of a new device for fetal tele-echography in isolated medical centers.

1.2 Methods

fetal tele-echography and Doppler was performed using, a) a portable echograph which setting and function (Doppler pulsed and color, 3D capture..) can be operated from away via internet, b) equipped with motorized probes (400g, 430cm³) which transducer can be orientated from away by an expert also via internet. The pregnant were in medical center far away from the expert center.

1.3 Results

two patient and expert centre were used for testing the feasibility of fetal tele-echography: Hospital of Ceuta (South Spain) with Tours Hospital (France) as expert center (1800km away), and the dispensary of Apatou (40km inside Amazonian forest, French Guyana) with St Laurent du Maroni (Sea border French Guyana) as expert center. At the patient site there was a midwife not trained for practicing echography, whose role was to hold the probe on the pregnant at the location indicated by the expert and to maintain it motionless. Fifteen

pregnancies were remotely investigated 10 located in Ceuta (23 to 36w GA) and 5 located at Apatou dispensary (10-34w GA). In each case the expert could visualize the fetal head (biparietal) the abdomen (transverse), the femur, the placenta and the umbilical chord and measure de corresponding parameters. The time duration of tele-operated echography was 15 to 20 min. Umbilical Doppler was performed in 6 pregnancy.

1.4 Discussion

the light tele-operated echograph and probe allowed to perform easily and in a limited time fetal echography and Doppler on pregnant far away from the expert. The system required only domestic internet between the expert and patient site.

1.5 Keywords

Fetal echography; Tele-Medicine; Tele-Echography; Tele-Operated Probe; Tele-Operated Echograph

1.6 Abbreviations

f/s: Frame per second; GA: Gestational age; GP: General practitioner; MHZ: Mega hertz; PC: Personal computer; RF: Radiofrequency; USB: Universal serial bus; W: week; Kb/s: Kilo bits per second; Mb/s: Mega bits per second; 3D: 3 dimensional.

2 Introduction

Echography and Doppler are the first imaging modality

which can be setup without huge and costly installation but the examination has to be performed by a Medical Doctor specially trained for Echography and Doppler (A Sonographer). Moreover the sonographer must be specialized in echography/Doppler in various domain like abdominal, pelvic, vascular, fetal echography. Thus it is evident that such multi-disciplinary sonographer cannot exist in isolated medical center with limited facilities and served by only some general practitioners (GP) assisted by nurses and midwife. Thus remote echography and Doppler could be of great help for the GP to identify very quickly emergency situation to be transferred immediately and other that can be treated on place. Access to remote echography will facilitate and make safer the medical diagnosis, which may result in a quicker decision making and a better medical assessment.

Several method were designed and validated for providing remote ultrasound examination to isolated subjects and patient. These methods were based on tele-operated systems (Arbeille et al., 2005; 2016, Georgescu et al., 2015; Vieyres et al., 2003), remote analysis of video capture, or remote guidance through videoconferencing (Awadallah et al., 2006; Hamilton et al., 2011; Otta et al., 2012; Randolph et al., 1999) or volume capture with 3D reconstruction (Arbeille et al., 2014; Kratochwil et al., 2000; Masuda et al., 2001).

A new compact system with a tele-operable light echograph (setting and function controlled from away) equipped with motorized probes (transducer orientation controlled from away) was tested for fetal tele-echography and Doppler. It was hypothesized that this compact and simplified system requiring only domestic Internet, and a “non sonographer” operator by the side of the patient, will be sufficient for performing remotely a reliable fetal echography.

3 METHODS

3.1 Portable Echograph and probe Tele-operated

A commercially available echograph (Orcheolite, Sonoscanner, Paris, France) was modified to allow for tele-operation through an Internet connection (Teamviewer, Goppingen, Germany) (Figure 1-3). At the expert site, the trained sonographer adjusted the settings (gain, depth, etc.) and functions (Doppler, colour, 3D, etc.) of the echograph using a standard PC keyboard. Each setting or function of the echograph was identified by a letters on the keyboard, for example <F6> and <F7> increased and decreased gain where <F4> activated the PW Doppler mode. The design and weight (6kg) of the echograph was not altered; however, additional functions were added to the operation including elastography, 3D reconstruction, Panoramic, and radio frequency (RF) display and process.

Two specialized tele-operated probes were developed (Vermon, Tours, France) for this system which were similar to commercial 3D probes, but slightly larger and heavier (400cm³ and 430g). The first motorized probe (for deep organs abdomen and fetus) contained a convex array transducer (3.5-7MHz) providing a wide image used for the assessment of deep organs (Figure 4-6). This probe was tele-operated using one motor to tilt the transducer (+55° to -55°) and a second to rotate the transducer around the central axis (+/-180°). The second probe contained




Figure 1: (a) Motorized probe (400cm³ and 430g). The transducer (3,5MHz curved array) can be remotely tilted and rotated (arrows) from away by the expert while manipulating (b) the dummy probe (arrow) (c) the tele-operated portable Echograph(6kg) and tele-operated probe (arrow).

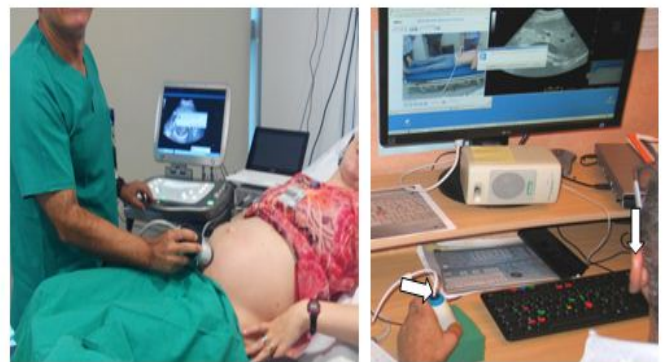

Figure 2: a) The patient site with the non-sonographer operator (midwife) holding the motorized probe on the pregnant and b) the expert site with the expert sonographer manipulating the dummy probe with his left hand (arrow) and selecting the ultrasound function on the keyboard with his right hand (arrow). On his screen the ambient video from the patient site with the pregnant and the midwife, and the echographic video.

a linear array transducer (5-15MHz) used for the assessment of superficial organs. In contrast to the convex probe, the linear transducer was only tele-operated using one motor for the tilt movement (+55° to -55°) as it was believed that the non-sonographer operator would be able to identify the long and shot axes of the superficial organs of interest (blood vessels, muscles). The probes were connected to the echograph using the standard probe connector through which the echograph sent the order sent by the expert to change the orientation of the transducer. Using custom software (Optimalog, St. Cyr-sur-Loire, France), movements of a dummy probe located at the expert site were mimicked by the transducer of the motorized probe at the patient site (Arbeille et al 2016).

Two IP camera (IP AXIS camera, Paris, France) allowed the expert sonographer to communicate with the non-sonographer operator at the patient site. A switch was used to control simultaneously the Internet connection for the portable computer, the echograph, and the IP Camera.

At the expert site (Figure 2), a basic portable computer, connected




Figure 3: a) Apatou dispensary (Amazonian forest, French Guyana) b) Pregnant, midwife, tele-echograph and motorized probes

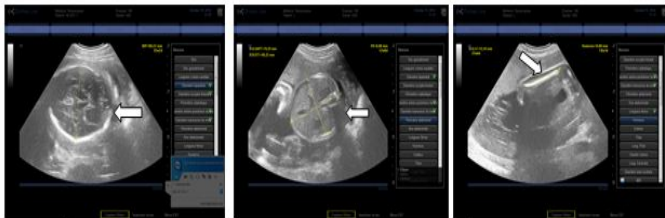

Figure 4: a) Biparietal view b) Transverse abdominal view c) Femur view, and measurements.

to Internet, was used to tele-operate the echograph and motorized probe and for the videoconference (IP AXIS camera, Paris, France) between the two sites. The dummy probe was connected to this computer via a USB plug.

3.2 Fetal tele-echography procedure

The patient site Doctor (GP) call the Expert approximately 1h prior to the Fetal Tele-echography and presents the clinical status of the pregnant and schedule the examination. When the pregnant is ready the patient site operator (GP, midwife) open the Internet connection and check with the expert that he receive the ambient video (to see and talk to the pregnant or the GP) as well as the fetal echographic video.

The Expert tells the distant operator to locate the motorized probe close to the Umbilic, and turn around 360° slowly in order to identify where the acoustic windows for the fetal head, abdomen, femur chord... are. Each acoustic window is identify by an hour (3h, 5h, 9h...) like on a clock centered on the Umbilic. Then the expert ask the operator to locate the probe at each desired acoustic window and at each of these location to maintain the probe motionless, vertical to the skin, while the expert tilt and rotate the transducer until he get the expected fetal view (biparietal, transverse abdomen, femur...). The expert adjust the gain, depth... on the echographic image and freeze and store the image. When the perfect view is frozen the expert can measure distance, surfaces... and store these data. In the case of Umbilical Doppler the operator locate the probe at the level of the placenta acoustic window, and the expert orientate remotely the transducer and activate the color Doppler mode to visualize the umbilical arteries and vein. Then he locate the pulsed Doppler

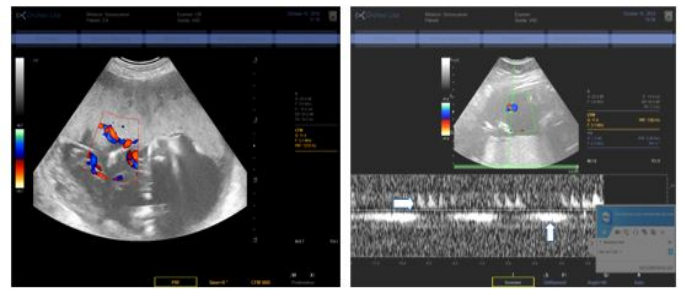


Figure 5: a) Placenta, and umbilical flow in color b) Pulsed Doppler: Umbilical artery and vein velocity spectrum .

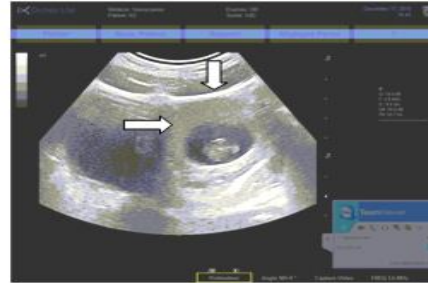


Figure 6: Example of fetal tele-echography of an 8 GA pregnancy, with poor satellite communication. The upper and left border of the uterus is not clearly display, such image could be improved by giving the priority to the quality of the image.

sample volume inside the vessel and trigger the pulsed Doppler mode. Lastly the Expert adjust the Doppler gain, the spectrum baseline, the frequency scale, the sample volume size... On the frozen Doppler spectrum the expert can measure systolic, diastolic velocities, vascular resistance indices.

4 RESULTS

4.1 Population

Two patient and expert centre were used for testing the feasibility of fetal tele echography: hospital of Ceuta (Spanish city, south limit of Europ) with Tours Hospital (France) as expert center (1800km away), and the dispensary of Apatou (40km inside Amazonian forest, French Guyana) with St Laurent du Maroni (Sea border french Guyana) as expert center. The link between Ceuta and Tours was a ground Internet while between Apatou and St Laurent du Maroni a satellite Internet was used.

At the patient site there was an operator (a midwife) not trained at all for practicing echography.

The tele-echography test was approved by the Ethical committee of the area where the tele -echography took place (Heath Regional Agency = ARS Agence Regionale de Sante). Each patient were informed about the protocol of Tele-echography and signed a formal consent form.

Fifteen pregnancies were remotely investigated, 10 located in Ceuta (23 to 36w GA) and 5 located at Apatou dispensary (10-34w GA).

The duration of the tele echography was limited to 20min because this examination was followed by a conventional echography by

a sonographer.

4.2 Fetal tele-echography performances

In each case the expert could visualize the fetal head (biparietal) the abdomen (transverse section), the femur (long axis), the placenta and in 6 cases the umbilical chord (color Doppler), and measure the corresponding parameters (Biparietal diameter, Abdomen diameters, Femur length, umbilical Doppler velocities).

The quality of the image reaching the Expert center was not different than the quality of those stowed directly into the Echograph at the patient site except in the case of satellite Internet but in this case the quality was restored by giving the priority to the quality image while losing partially the realtime display.

The time duration of tele-operated echography was 15 to 20 min for the pregnant in Ceuta while the duration was slightly longer (some minutes) for the patient in Apatou as the satellite Internet introduced a delay up the 3-4 s.

Doppler of the umbilical flow was performed in 6 of the pregnancies, and voluntarily not on every pregnancy as the Tele-echography duration was limited to 20min for ethical reason as this examination was followed by a conventional echography.

5 DISCUSSION

The new light tele-operated echograph and probe allowed to perform easily and in a limited time fetal echography and Doppler on pregnant far away from the expert. The system required only domestic internet between the expert and patient site and no competence in echography at the patient site.

5.1 Technical consideration

at the patient site (distant or isolated) the tele-operated system is compact (Commercial portable echograph modified; Figure 1) and light: 6kg, plus 2 probes of 400g, 430cm³ each. The probe size and weight make it very easy to manipulate especially for paramedics who most of the time are women. Moreover the light weight allow the distant operator to locate it accurately at the place indicated by the expert and to translate it by 1, 2 cm at the request of the expert.

5.2 Patient comments

The motorized probe aspect is not really different from a conventional 3D probe and thus do not generate any additional stress compare to a conventional echography. None of the patient refused the tele-echography and after the examination they did not report any discomfort. The video conferencing allowed the patient and the Expert to talk together and to see each other all along the tele-echography, which contributed to maintain the link between the sonographer and the pregnant. With the tele-echography the pregnant did not have to travel to have the echography nor to wait for an appointment at the radiological center, and was informed very rapidly on the fetal growth and behavior.

5.3 Environment required

The tele-operated system requires 220/110 volt electrical supply, and a domestic Internet, in the present test 256Kb/s to 1Mb/s were found sufficient. In case of poor Internet the Expert gave priority to “the refreshment rate” of the image while searching for the appropriate fetal organ view (Ex: bi-parietal, transverse abdomen...). Then without moving the probe transducer he switched to “priority to the image density” (quality) which allowed him to get an acceptable image for the diagnosis. In the present test we had most of the time 1Mbit/s bandwidth with a frame rate of 10f/s and a delay of 2s, which was sufficient for getting echographic images and Doppler data quite in realtime and of good quality for diagnosis.

The quality of the image reaching the expert office was very high and close to the quality of the image recorded in the Echograph of the patient site, at least when the Internet flow rate was higher than 512 kb/s and the frame rate around 10 f/s. Thus the compression/decompression and the other processing of the images/video while traveling on Internet did not affect significantly the brightness, contrast or resolution of the echographic image. In case of poor Internet the delay was higher and the priority was given to the image density, the examination was longer but the quality of the echography remained acceptable.

5.4 Required competency for the distant operator

No specific training nor ultrasound knowledge was required for the operator by the side of the patient. The Echograph and the probe orientation being fully controlled (tele-operated) from away by the expert, the distant operator task was limited to locate the probe at the acoustic window of the organ to be investigated. Thus any person with basic knowledge of anatomy could serve as an operator. Additionally because there is no need for any training for the distant operator, he can serve any expert for any kind of echography for abdominal, pelvic, vascular, fetal, superficial organs... Consequently any patient in isolated site can have access anytime to all type of echography tele-operated by an expert of the organ and of the pathology investigated.

5.5 Other applications

In case there are GP or paramedic more or less trained or with limited practice (because not too many opportunity to preform echography in isolated medical center), the system allow a control of their echographies by an expert to secure the diagnostic. Lastly the system could be used for training remotely future sonographers still under training or to confirm the diagnostic of another distant sonographer in case of difficult diagnostic (Tele-echography for second opinion between sonographers).

5.6 Cost of installation

Presently the equipment for the patient site “Tele echograph and probes” can be purchased at Sonoscanner Cie (Paris, France) around 50 K € that is to say 20 K€ more than a simple portable

Echograph. The equipment of the Expert site is limited to a portable PC (approx. 0,5K€) to which the dummy probe (1K€) is USB connected. The expert center equipment is movable as it requires only a domestic Internet access, thus it can be activated from various places: home, vacation places, hotel... which allow any Expert to perform a tele-echography in emergency wherever he is.

5.7 Integration of the tele-echography modality in the health care system

An expert center can manage several patient site (5 to 10). Our estimation concluded that a Health House (General population in rural areas) schedule 2 to 3 tele-echography per day while a Senior Living Communities (Patient higher than 80 year) schedule 1 tele-echography per week. Presently these patient even the oldest ones have to get an appointment at a radiological center for the echography and to travel 40–60km (total 3-4h). The estimation concerning isolated dispensary in Guyana reported approximately 1 general or obstetrical echography per day. Presently the dispensary are visited by a sonographer (who carry the echograph in the pirogue...) once a month, thus in case of suspected emergency the patient has to be transferred by helicopter with the risk to order the transfer too late or for nothing. A one year practice in a Health House have shown that the use of tele echography in routine (for abdomen, pelvis, vessels, small parts) did not increase the number of echography.

5.8 Other methods for tele echography

Fifteen years ago a robotic arm to which an echographic probe was fixed and which was tele-operated from away was designed by our lab (Vieyres et al 2003). This system was successfully tested for fetal echography in 2005 but the device was heavy and big and had to be suspended to a mechanical support (Arbeille et al 2005). The whole device was difficult to move and rather impressive for the pregnant. The other methods proposed were based on the processing of echographic video or on the processing of volumic recordings (3D) or used remote guidance through video-conferencing (Awadallah et al., 2006; Hamilton et al., 2011; Otta et al., 2012; Randolph et al., 1999, Arbeille et al., 2014; Kratochwil et al., 2000; Masuda et al., 2001). Unfortunately most of these method could not provide a realtime tele-echography, except the remote guidance but this method was too much time consuming and in fact works only if the distant operator had been trained for fetal echography.

6 CONCLUSION

Presently, the medical reliability and usefulness of tele-echography for isolated patients has been demonstrated for general and fetal echography and Doppler. The control of the echograph setting and functions with the use of the motorized probe improved both the time required for the examination and the quality of the echographic and Doppler data. The motorized probe and tele-operated echograph also provided a method

of tele-echography that can quickly generate reliable diagnoses while requiring no training of the operator at the patient site.

7 ACKNOWLEDGEMENT

The authors thanks Mme M Porcher and Roselyne Claveau (Assistantsonographer) and Mr Joel Blouin (engineer) for their active contribution.

8 DECLARATIONS

8.1 Ethical approval

The tele echography study was approved by the Ethical committee of the area where the tele echography took place (Heath Regional Agency = ARS Agence Regionale de Sante). Each patient were informed about the protocol of Tele echography and signed a formal consent form.

9 REFERENCES

1. Arbeille P, Ruiz J, Herve P, Chevillot M, Poisson G, Perrotin F. Fetal tele-echography using a robotic arm and a satellite link. *Ultrasound Obstet Gynecol.* 2005;26(3):221-226. DOI:10.1002/uog.1987
2. Arbeille, P, K Zuj, A Saccomandi, J Ruiz, E Andre, C de la Porte, G Carles, J Blouin, M Georgescu..Tele-Operated Echograph and Probe Transducer For Remote Ultrasound Investigation On Isolated Patient (study on 100 Cases). *Telemed J E Health.* 2015;22 (7):599-607. DOI: 10.1089/tmj.2015.0186.
3. Arbeille, P, Fornage B, Boucher A, Ruiz J, Georgescu M, Blouin J, et al. Vincental. Tele sonography: Virtual image processing of remotely acquired abdominal, vascular, and fetal sonograms. *J Clin Ultrasound,* 2014;42(2):67-73. DOI: 10.1002/jcu.22093.
4. Arbeille P, Zuj K, Saccomandi A, Andre E, De La Porte C, Georgescu M. Tele-Operated Echography and Remote Guidance for Performing Tele-Echography on Geographically Isolated Patients. *J Clin Med.* 2016;5(6):E58. DOI: 10.3390/jcm5060058.
5. Awadallah S, Halaweish I, Kutayli F, Tele-echocardiography in neonates: utility and benefits in South Dakota primary care hospitals. *S D Med.* 2006;59(3):97-100.
6. Georgescu M, A Saccomandi B, Baudron, Arbeille Ph, Remote Sonography In Routine Clinical Practice Between Two Isolated Medical Centers And The University Hospital Using A Robotic Arm (A One Year Study). *Telemed J E Health,* 2016;22(4):276-281.
7. Hamilton, D.R. On-orbit prospective echocardiography on International Space Station crew. *Echocardiography,*2011;28:491-501. DOI: 10.1111/j.1540-8175.2011.01385.x.
8. Kratochwil A, Lee A, Schoisswohl A. Networking of three dimensional sonograph volume data. *Ultrasound Obstet Gynecol.* 2000;6:335-340.

9. Masuda, K. et al. Three dimensional motion mechanism of ultrasound probe and its application for tele-echography system. Proceedings of International Conference of the IEEE Intelligent Robot and Systems. 2001;:1112-1116.
10. Otto C.A, Shemanski R, Drudi L. Real-time tele-echocardiography: diagnosis and management of a pericardial effusion secondary to pericarditis at an Antarctic research station. *Telemed J E Health*. 2012;18:521-524.
11. Randolph GR, Hagler DJ, Khandheria BK, Lunn ER, Cook WJ, Seward JB. et al. Remote telemedical interpretation of neonatal echocardiograms: impact on clinical management in a primary care setting. *J Am Coll Cardiol*. 1999;34(1):241-245.
12. Vieyres P, Poisson G, Courrege F, Merigeaux O, Arbeille Ph. The TERESA project: from space research to ground tele-echography. *Industrial Robot: An International Journal*. 2003;30(1):77-82.